



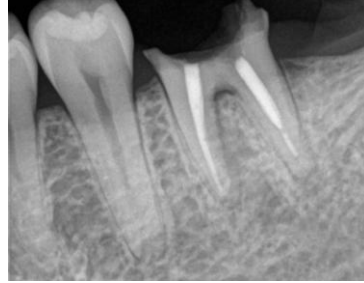
Shadi Abedin, DDS, CAGS
Roots Houston Endodontics
1001 West Loop S., Ste. 895
Houston, TX 77027
(713)227-6687 (ROOTS)
www.RootsCanal.com

August 5, 2015

Dear Dr. Baba



We saw your patient
Mr. Wesley Walz for a consultation.
Thank you for your referral.



Tooth:
Date of consultation:
Prognosis:

19
8/5/2015
Guarded

Notes:

Consultation on tooth #19. Patient said that his crown fell off about 3 months ago. He also explained that he has had trouble with keeping this crown on since the time that the crown was originally cemented. Explained all treatment options to patient. Recommended re-treatment of tooth #19 and new crown if patient decides to save the tooth. Also described alternative treatment option of extraction with possible implant. Long term prognosis is more ideal with implant option. Patient will review options and make a decision on his course of treatment. Rx: Motrin 600 mg, Amoxicillin 500 mg.

Sincerely,

Shadi Abedin, DDS CAGS