



Date: February 10th, 2017

Patient Name: Andrew Raines **DOB:** April 1st, 1972 **Gender:** Male

Scanning Center: CT Dent Ltd

Referring Doctor: Dr Gavin Laidlaw

Date of Scan: December 28th, 2016

Images provided: Cone Beam CT images of the maxilla and mandible

Scanning device: I-CAT

Clinical Info:

Relevant History: Please assess scan for any pathology

Client Notes:

Findings:

Paranasal Sinuses: presence of multiple small mucous retention cysts in the maxillary sinuses

Nasal Cavities: No abnormalities detected

Airway: No abnormalities detected

Temporomandibular Joints: Both joints are well visualized and no abnormalities are detected

Osseous Structures: No abnormalities detected

Dental findings:

Maxilla: presence of a periapical lesion on 23. Residual root tips are noted in the area of 24 and 27

Mandible: periapical lesion with complete periodontal bone loss on the buccal aspect of 31
Widening of PDL space on all aspects of the root of 41 and the apices of 36 is noted

Impressions and recommendations:

Prognosis of 31 is poor, clinical assessment is needed for 41.

Removal of the roots of 24 and 27 and the residual dental material in the area of 25 is needed as well.

Endodontic treatment is needed for 36 and 23

Mucous retention cysts are common findings they do not require any additional assessment

Radiologist name and signature:

Thank you for the referral of this patient and the opportunity to serve your practice.

Marcel Noujeim DDS, MS

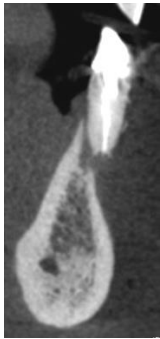
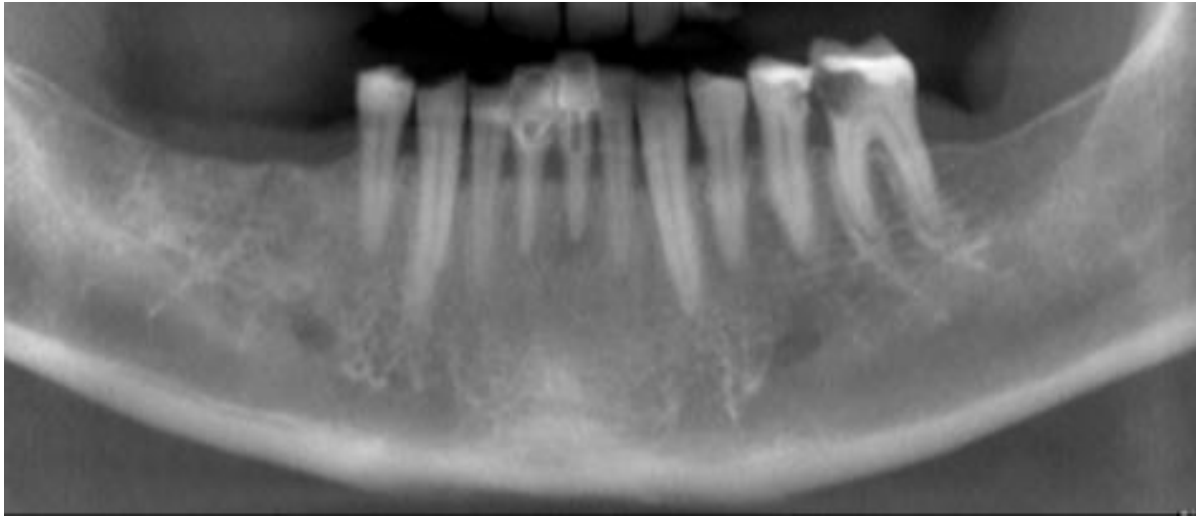
Diplomate, American Board of Oral & Maxillofacial Radiology

Phone: 617-820-5279

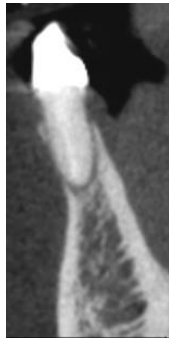Email: Info@3ddx.com www.conebeam.com

Web: www.3ddx.com

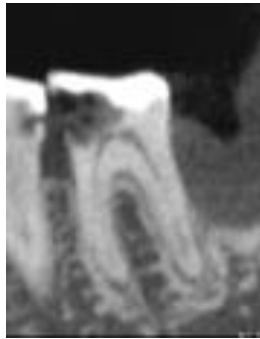3D Diagnostix inc
167 Corey rd. Suite #108
Brighton, MA 02135



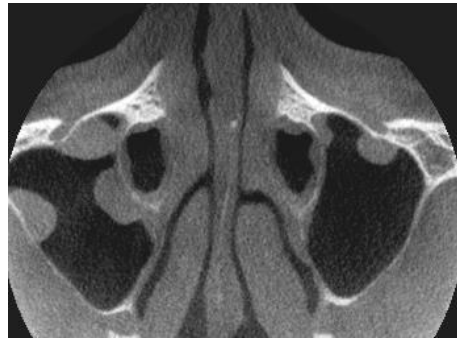
31



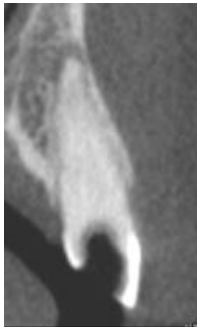
41



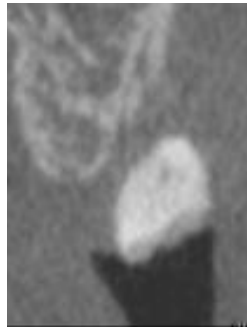
36



Maxillary sinuses



23



27

